Computer-aided detection of the most suitable MRI sequences for subsequent spinal metastasis delineation

Georg Hille[1], Steffen Serowy[2], Klaus Tönnies[1], Sylvia Saalfeld[1]

[1]Department of Simulation and Graphics, University of Magdeburg, Germany
[2]Department of Neuroradiology, University Hospital of Magdeburg, Germany
georg.hille@ovgu.de

Abstract. Detection and segmentation of vertebral metastases is a crucial step for support of diagnosis and treatment planning, especially in minimally invasive interventions. Even though computer-assistant tools will not dispense radiologists yet, algorithmically supported detection and segmentation of spinal metastases will play a more and more important role in the near future. The usage of images, where a sufficiently good differentiation between metastases and surrounding tissue is possible, constitutes a critical requirement for successful segmentation procedures. Therefore, we proposed a pipeline, that semi-automatically sorts out unsuitable imaging sequences, as well as combinations of different images via absolute intensity difference images and returns a ranking based recommendation of which image data fits best the requirements for future segmentation tasks. We evaluated our method with 10 patient cases and matched the produced ranking with those of a segmentation field expert. With an average Spearman's ranking coefficient of 0.92 ± 0.07, our method showed promising results and could be a valueable pre-processing step to speed up clinical segmentation procedures due to omitting the time-consuming manual initialization of choosing suitable image data.

1 Introduction

Owing to the fact that cancerous diseases will be more frequently than ever and metastases located in the spine predominate while being the third most organ to metastasize [1] after lungs and liver [2], spinal metastases treatment will become invariably a more urgent task. The steadily growing amount of image data, which is acquired for diagnostical and therapeutical purposes will further increase workload of radiologists, hence the calls for assistance are getting louder. Furthermore, the detection and segmentation of vertebral metastases is a pivotal step towards diagnosis and treatment planning such as radiofrequency ablation simulation. Even though computer-assistant tools will not dispense yet the need for verification by radiologists, it gains more and more appreciation for pre-processing image data and decision support during diagnosis and therapy. Bone tumors and metastases typically replace focal bone marrow, which can

be visualized in magnetic resonance imaging (MRI). Dependent on the neoformation type, metastases cause characteristic signal intensities in different MR imaging sequences, arising the indispensable need for acquiring various sequences [3] during the diagnostic process to locate and assess the extent of the pathologic neoformation. For example segmentation of spinal metastases done manually is time-consuming and fatiguing considering the number of image slices and sequences acquired per patient. This leads to the importance of algorithmically assistance. Though, massive obstacles for metastasis segmentation in spine MRI are poor image contours between pathologic and healthy tissues, signal variations of the metastases and deformations due to the metastatic bone alteration. Therefore, an suitable MR sequence has to be chosen by the clinician. To simplify segmentation of anatomical structures and tissues, a sufficiently good differentiation is crucial, whether by pronounced object contours or average signal contrast towards surrounding tissues. The aim of our work is to find the most suitable MRI sequences or combination of various sequences of each patient via absolute intensity difference (AID) images for subsequent spinal metastasis segmentation procedures. Thus, our method will semi-automatically determine images with preferably high image contrast between metastases and both healthy vertebrae and discs and result in a recommendation of which image data fits best the requirements for following segmentation tasks.

2 Materials and Methods

Our method starts with image fusions of all sagittal acquired MR sequences of each patient. All image volumes were isotropically up-sampled towards the in-plane resolution of the reference image (T_1-weigthed sequence) and rescaled to an 8-bit grayscale image. Related work, such as presented by Koh et al. [4] demonstrated earlier that absolute intensity difference images of variously weigthed MR sequences could pronounce tissue signals compared with native imaging sequences. Therefore, we computed all possible combinations of AID-images and included them in our study. Subsequently, we manually placed a landmark in a selectable sagittal cross-section of a single reference image in each, the diagnosed metastasis, a vertebral disk and one healthy vertebra. By cubic regions of $5 \times 5 \times 5\,\mathrm{mm}$ extent with the landmarks as center points, we could estimate local intensity features of each MR sequence and the computed AID-images. A preferably good differentiation between various tissue signals could be defined as a contrast or dissimilarity maximization problem. Hence, we searched for the MR sequence or AID-image, with the highest dissimilarity between metastasis and both vertebra and disk within joint cumulative histograms of all three tissue types (see Fig. 1). As a dissimilarity measure we used correlation distance:

$$d_{st} = 1 - \frac{(x_s - \bar{x_s})(y_t - \bar{y_t})}{\sqrt{(x_s - \bar{x_s})(x_s - \bar{x_s})'}\sqrt{(y_t - \bar{y_t})(y_t - \bar{y_t})'}}. \tag{1}$$

with $\bar{x_s} = \frac{1}{n}\sum_j x_{sj}$ and $\bar{y_t} = \frac{1}{n}\sum_j y_{tj}$ and x_s and y_t as distances between both bin count vectors.

Since most metastases show hypointense signals in T_1- and partially also in T_2-weigthed images in comparison with healthy bone structures, but isointense signals towards vertebral discs, we weighted the dissimilarity between metastasis and the latter somewhat higher. Therefore, both distances were weigthed in the ratio $1 : 2$ in favour of the distinction between metastasis and vertebral disk. We ranked the produced results of each patient according to the maximum correlation distances within their MR sequences or AID-images. To evaluate our method, we matched the algorithmically determined rankings with those of a segmentation field expert. It was asked, which three MR sequences or AID-images would be the most suitable for further treatment planning. We considered only to select the top three images per case due to the difficulty to subjectively rank images with hardly distinguishable tissues (where $d_{st} < 0.1$). Our evaluation set consisted of 10 patients, who underwent radiofrequency ablations of spinal metastases, with at least three pre-interventional acquired MR sequences per case: T_1, T_2, STIR and/or contrast enhanced T_1. To check the accordance of both rankings, we modified Spearman's ranking coefficient (SRC) in order to compensate the difference in observation numbers:

$$r_s = 1 - \frac{6\sum_{i=1}^{n_E} d_i^2}{n_d(n_d^2 - 1)}. \tag{2}$$

with d_i as the difference between two ranks of each observation and $n_d = n_A - n_E$ as the difference between the number of observations from our algorithmically produced ranking (n_A) and the number of observations from the expert (n_E). High SRC scores mean, our method prefers similar imaging sequences regarding to following segmentation tasks as a field expert would do.

3 Results

The overall Spearman's ranking coefficient between the algorithmically and the manually produced ranking of the suitability of certain MR sequences for further treatment planning, e.g. segmentation tasks, was 0.92 ± 0.07. The worst result was a ranking coefficient of 0.75. However, in this particular case the maximum correlation distance of the cumulative histograms of all sequences and AID-images was below half of the overall average (d_{st} of 0.15 vs. $d_{st,mean}$ of 0.32), thus, a clear differentiation between metastasis and both vertebra and disk was hardly possible. If there was no prominently suitable sequence or AID-image with a good distinction between those tissues, the chances of establishing similar rankings decreased and therefore, achieving lower ranking coefficients was expectably. Whenever there was a correlation distance above 0.25 within the joint cumulative histograms, the Spearman's ranking coefficient was above 0.90, meaning our approach found suitable images, similar to the field expert (see Tab. 1). Such

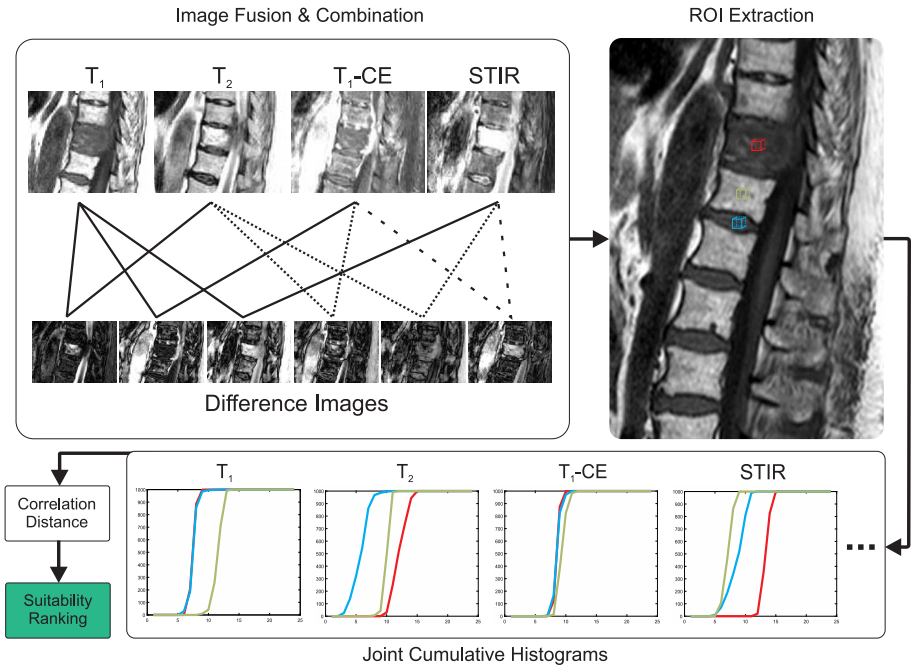

Fig. 1. The pipeline of our proposed methodology. Following image fusions of all available sagittal MRI sequences, regions of interest for each tissue were extracted. Subsequently, correlation distances of the curves were calculated in joint cumulative histograms of the metastasis (red), vertebra (green) and disk (blue) regions of each MRI sequence and their AID-images, leading to a ranking of the suitability of the images for following segmentation tasks.

high accordance was achieved in two cases even though the maximum correlation distance was below 0.25 (patient case 3 and 5). Furthermore, the only two cases with a SRC score lower than 0.90 had a maximum correlation distance below 0.20 (patient case 2 and 6), meaning there is hardly any tissue delimitation possible. Therefore, our test set showed that high correlation distances ($d_{st} > 0.25$) guaranteed to find the most suitable sequences or AID-images, although lower distances could score a hit.

4 Discussion

Patient cases with hardly a signal emphasizing of cancerous structures in all imaging sequences mean an extremely ambitious challenge for automatically or even semi-automatically performed segmentation methods. The usage of images that allow a sufficiently good differentiation between metastases and surrounding tissue constitutes a critical requirement for segmentation procedures. For this purpose we determined correlation distances in joint cumulative his-

Table 1. Spearman's ranking coefficient and the maximum correlation distance per case

	Patient Cases									
	1	2	3	4	5	6	7	8	9	10
SRC	0.955	0.754	0.952	0.978	0.933	0.866	0.911	0.918	0.933	1
$d_{st,max}$	0.570	0.154	0.194	0.511	0.108	0.184	0.294	0.402	0.275	0.471

tograms of metastases, vertebrae and discs and ranked them according to their tissue discriminability. These rankings were matched with those of an expert and the SRC scores showed high accordance, which means our method prefers suitable sequences or AID-images similar to the field expert. Our evaluation showed promising results for recommending such sequences out of a bunch of diagnostically acquired images, as long as there are some that are preferable. For this purpose the user only has to place three ROIs around and within the diagnosed metastasis in a single MRI sequence instead of examining every available image. This pre-processing step could speed up semi- or fully automatic segmentation procedures due to omitting the time-consuming manual initialization of choosing reasonable images.

Acknowledgements This work was supported by the German Ministry of Education and Research (13GW0095A) within the *STIMULATE* research campus.

References

1. Witham TF, Khavkin YA, Gallia GL, Wolinsky JP, Gokaslan ZL. Surgery insight: current management of epidural spinal cord compression from metastatic spine disease. Nature clinical practice Neurology. 2006;2:87–94.
2. Klimo P, Schmidt MH. Surgical management of spinal metastases. The Oncologist. 2004;9:188–196.
3. Guillevin R, Vallee JN, Lafitte F, Menuel C, Duverneuil NM, Chiras J. Spine metastasis imaging: review of the literature. Journal of neuroradiology. 2007;34(5):311–321.
4. Koh J, Chaudhary V, Jeon EK, Dhillon G. Automatic spinal canal detection in lumbar MR images in the sagittal view using dynamic programming. Computerized Medical Imaging and Graphics. 2014;38(7):569–579.